



DATE PRESENTING CLINICAL SIGNS

12/17/21

Weight loss of 6 lbs since September. Was eating, but less. Not isn't eating much at all. On Cerenia, Mirtazapine.

BW (12/6): ALT 271, ALP 309, GGT 3, T Bili 1.0. BUN 9, Creat 1.6, TP 8.5, Glob 5.4, A:G ratio 0.6.

UA: SG >1.040, Prot 30, Glucose 50, Ketones 15, Bili 6, Urobil 12, Blood 50.

INTERPRETED BY

AUS: Splenomegaly with mild scalloping contour. Liver hyperechoic texture. Urolith in bladder.

L.D. McGill, DVM,
Ph.D, DACVP

CYTOLOGY SUBMISSION

Liver; Spleen

OBSERVATIONS

PATIENT

Toodles Durost

Liver: Submitted are a large number of excellent videos of cells collected from the liver in Toodles. The hepatocytes are rather consistent throughout all of the aggregates of hepatocytes identified. All of them have large vacuoles in their cytoplasm with lipid. The vacuoles are slightly irregular but prominent. A very few inflammatory cells are associated with the hepatocytes.

SPECIES

Feline

Spleen: Submitted are many excellent videos of cells collected from the spleen in Toodles. The cellularity is rather consistent with a mixture of cells. There are neutrophils, nucleated RBCs, lymphocytes and scattered macrophages. There is a prominent RBC background. There are irregular clumps of platelets, some of which are quite large. There are no changes supporting malignancy. The prominent neutrophils are evident in several fields.

BREED

DSH

INTERPRETATION OF THE FINDINGS & FURTHER RECOMMENDATIONS

Liver - Marked hepatocellular lipidosis with minimal inflammation.

Spleen - Mixed cell collection consistent with probable splenitis and congestion.

COMMENTS

SEX

Male Neutered

The changes in the liver support a rather severe metabolic liver disease process. In the cat, this is often associated with pancreatitis. It could also be the result of enteritis. There is no suggestion of malignancy or sepsis. Further evaluation for metabolic changes in Toodles is encouraged. Pancreatitis would be on the top of my list.

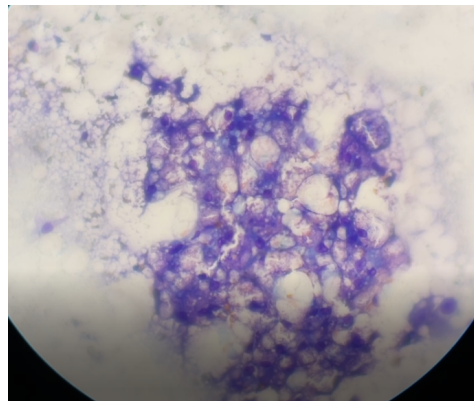
AGE

8 y

The changes in the spleen suggest chronic inflammation and congestion. I suspect that these changes are secondary. There is no suggestion of malignancy or sepsis in the spleen. The spleen is likely responding to the same irritation that is causing the hepatic lipidosis. Reestablishing alimentation may be of benefit in Toodles.

WEIGHT

11.1 lbs



HOSPITAL NAME

Scanvet

REFERRING VET

Dr. Lane

Image shows representative hepatocytes with lipidosis. These cells are rather severely involved.

INVOICE NUMBER

645



DATE

12/17/21

INTERPRETED BY

L.D. McGill, DVM,
Ph.D, DACVP

PATIENT

Toodles Durost

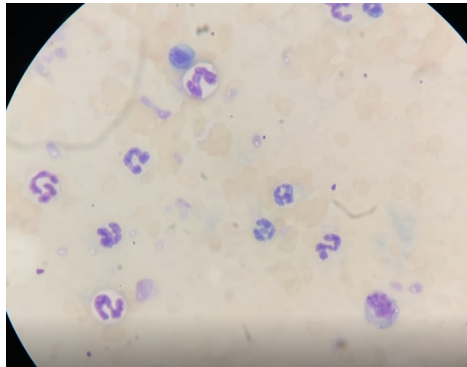


Image shows many cells in the spleen in Toodles. Neutrophils are prominent. There are no platelet aggregates in this collection.

SPECIES

Feline

The information and recommendations provided are based on the images presented by the referring veterinarian. No evaluation can be communicated regarding pathology that was not visible in the image/video clips provided.

BREED

DSH

Thank you for this referral. If the clinical or image interpretation does not parallel your findings or if I can be of any further assistance please contact me.

SEX

Male Neutered

L.D. McGill, DVM, Ph.D., DACVP
8288 Top of the World Drive
Cottonwood Heights, UT 84121
ldmcgill.vetpath@gmail.com
cell: 801-865-1220

AGE

8 y

WEIGHT

11.1 lbs

HOSPITAL NAME

Scanvet

REFERRING VET

Dr. Lane

INVOICE NUMBER

645